Urology Case Reports 33 (2020) 101293

Contents lists available at ScienceDirect

Urology Case Reports

journal homepage: http://www.elsevier.com/locate/eucr

Inflammation and infection

Xanthogranulomatous pyelonephritis caused by fusobacterium nucleatum. Case report and review of literature

Faris Abushamma [a,d,*], Robyn Perry-Thomas [d], Caroline Hammond [b], Alexander D Horsch [c], Tim Whittlestone [d]

[a] Department of Urology, An-Najah National University Hospital, An-Najah National University, Nablus, Palestine
[b] Infectious and Microbiology Department, Southmead Hospital, Bristol, United Kingdom
[c] Interventional Radiology Department, Southmead Hospital, Bristol, United Kingdom
[d] Bristol Urological Institute, Southmead Hospital, Bristol, United Kingdom

ARTICLE INFO

Keywords:
XGP
Urinary tract infection
Fusobacterium nucleatum
Renal calculi

ABSTRACT

Xanthogranulomatous pyelonephritisis (XGP) is a rare and aggressive form of chronic urinary tract infection. The most common microorganism is Proteus but other microorganisms have been described in the literature. In this article, we describe a sixty-year-old male who presented with urosepsis and sever thrombocytopenia secondary to Fusobacterium nucleatum urinary tract infection which led to poorly functioning XGP.

The rarity of the microorganism and the devastating clinical course encourages us to report it as anaerobes don't usually cause UTI but unusual microorganism should be suspected if the clinical course is atypical or if urinary tract abnormalities are present.

Introduction

XGP is a chronic and destructive granulomatous process of renal parenchyma which is associated with long-term urinary tract obstruction and infection. It is uncommon and often presents as asymptomatic renal mass. It can present as an acute urinary tract infection. Mostly caused by Proteus and other gram-negative bacteria and may lead to poorly functioning kidney unit.[1]

Fusobacterium bacteraemia is a very rare cause of UTIs, in which spread of infection is usually via the hematogenous route.[2] There are very few case reports of such infections available in the literature. However, in this article we describe a case of XGP caused by ascending Fusobacterium nucleatum.[3,4.]

Case presentation

A sixty-year-old male was transferred to our hospital with a seven days history of feeling generally unwell and left sided abdominal pain. He had a significantly raised body mass index (BMI) of>40. He also had a previous history of recurrent UTIs.

On initial presentation he was septic with orthostatic hypotension. Biochemical testing revealed raised inflammatory markers and severe thrombocytopenia (platelet count of 1 × 109/L). A CT-CAP revealed a 2 cm obstructing left pelvi-ureteric junction (PUJ) stone with left sided hydronephrosis, a peri-nephric collection and a splenic abscess. Fig. 1.

Blood cultures were taken and he was commenced on intravenous (IV) gentamicin prior to transfer to ICU for stabilisation. He received a platelet transfusion and IV immunoglobulin infusion. Urethral catheterisation was not possible as his penis was buried entirely between the suprapubic fat and scrotum, and the patient urinated through a tiny suprapubic skin slit. The patient then underwent left nephrostomy, splenic abscess drainage and suprapubic catheter (SPC) insertion in interventional radiology. Fig. 2.

Frank pus was obtained at the time of the nephrostomy and splenic drain insertion, and this was sent for microbiological examination.

Unexpectedly, initial blood cultures were positive for Fusobacterium nucleatum, an anaerobe which colonises the mucus membranes and is not usually associated with UTIs. Thus, antibiotic therapy was altered, as per microbiology advice.

The patient had no history of ear, nose or throat (ENT) infection and Doppler US imaging of the internal jugular veins were normal. Therefore, Lemieres disease was excluded and there were no other distant possible causes of septic emboli. Consequently, it was defined as ascending anaerobic UTI.

* Corresponding author.
E-mail address: f.abushamma@najah.edu (F. Abushamma).

https://doi.org/10.1016/j.eucr.2020.101293
Received 22 April 2020; Received in revised form 23 May 2020; Accepted 26 May 2020
Available online 3 June 2020

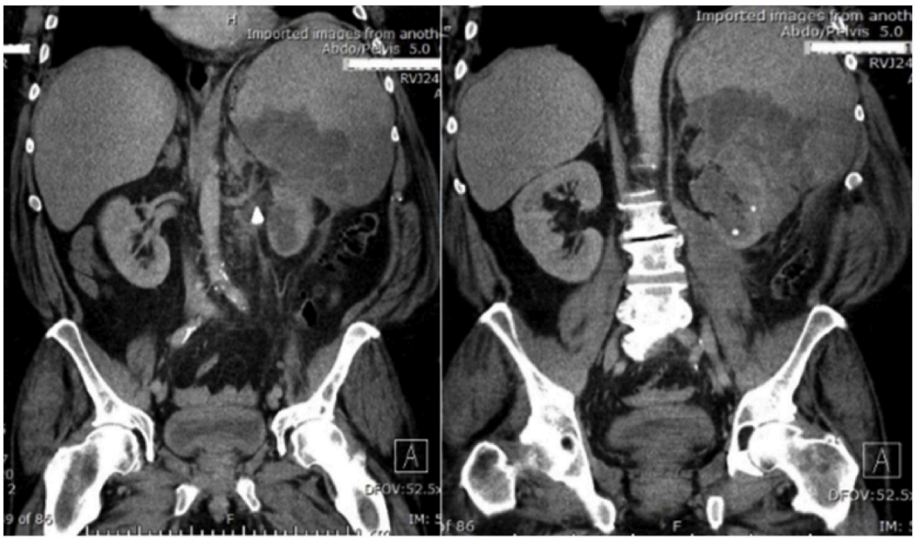

Fig. 1. Images from initial CT CAP.

Fig. 2. CT images following insertion of left nephrostomy, splenic drain and suprapubic catheter.

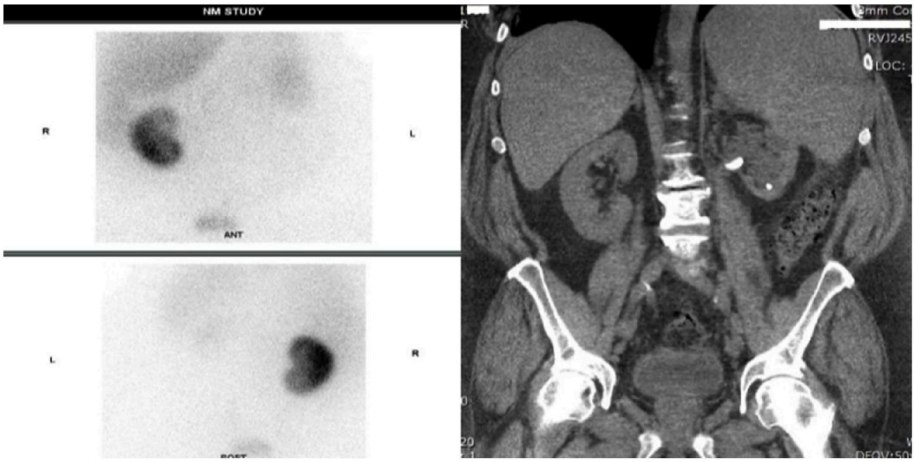

Fig. 3. DMSA scan and CT KUB (5 months later).

The patient made good clinical and biochemical progress (Platelets raise to normal) and was stepped down to oral antibiotics after a couple of weeks.

We concluded that the most likely cause of sepsis was a poorly functioning xanthogranulomatous (XGP) kidney secondary to a rare anaerobic infection as the urine output from the nephrostomy was less

than 100 ml/day .

5 months later DMSA scan and CT Kidney were done which showed poorly functioning hydronephrotic kidney secondary to persistent PUJ stone but resolved perinephric infection. Fig. 3.

A meeting with the patient and his family was arranged to discuss management options. Surgery (Nephrectomy) was declined by the patient and he opted to follow a conservative approach and symptomatic treatment.

Discussion

XGP is a rare, chronic destructive granulomatous process of renal parenchyma in association with long-term urinary tract obstruction. It can present with severe sepsis and is most commonly associated with Proteus ascending infection; however other microorganisms have been described in the literature.[1]

Fusobacterium bacteraemia is rare, accounting for less than one percent of bacteraemias and fusobacterium infections of the renal tract rarer still.[2] Only a few case reports of such infections have been previously published, mainly as hematogenous spread in Lemierre's syndrome but also demonstrated in a man with chronic renal allograft rejection reaction.[3,4]

In this case, we propose that the deformity of the patient's external genitalia, with a long standing buried external meatus, may have induced an ascending anaerobic urinary tract infection causing severe XGP.[5]

Although Fusobacterium nucleatum is an extremely rare cause of UTI, the diagnosis of anaerobic UTI should be considered in cases of urosepsis non-responsive to standard urosepsis antibiotics that do not provide anaerobic cover, especially if there is evidence of anatomical lower urinary tract abnormalities.

Conclusion

XGP is a rare form of chronic UTI with variant clinical course. Although most commonly caused by Proteus, other microorganisms have been reported. Unusual microorganism should be suspected if clinical course is atypical or not responding to standard antibiotics. Furthermore, although anaerobic infections are an infrequent cause of UTIs, which are spread via the hematogenous or the ascending route, it may have a devastating outcome if not recognised and managed appropriately early.

Ethical statement

Written informed consent was taken from the patient for publication of this case report and the associated images.

Declaration of competing interest

The authors have no conflicts of interest.

Acknowledgements

Thanks to Mr Salah Albuheissi, clinical lead of Bristol Urological institute, Bristol, UK for his constant support and encouragement.

References

1. Tolia BM, Iloreta A, Freed SZ, Fruchtman B, Bennett B, Newman HR. Xanthogranulomatous pyelonephritis: detailed analysis of 29 cases and a brief discussion of atypical presentations. *J Urol.* 1981 Oct;126(4):437–442.
2. Segura JW, Kelalis PP, Martin WJ, Smith LH. Anaerobic bacteria in the urinary tract. *Mayo Clin Proc.* 1972 Jan;47(1):30–33.
3. Su CP, Huang PY, Yang CC, Lee MH. Fusobacterium bacteremia: clinical significance and outcomes. *J Microbiol Immunol Infect.* 2009 Aug;42(4):336–342.
4. Aliyu SH, Yong PF, Newport MJ, et al. Molecular diagnosis of Fusobacterium necrophorum infection (Lemierre's syndrome). *Eur J Clin Microbiol Infect Dis.* 2005 Mar;24(3):226–229.
5. Ribot S, Gal K, Goldblat MV, Eslami HH. The role of anaerobic bacteria in the pathogenesis of urinary tract infections. *J Urol.* 1981 Dec;126(6):852–853.